

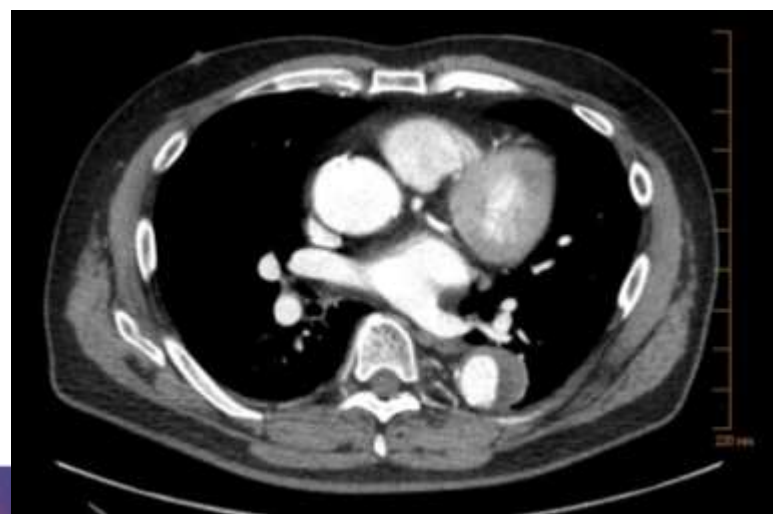
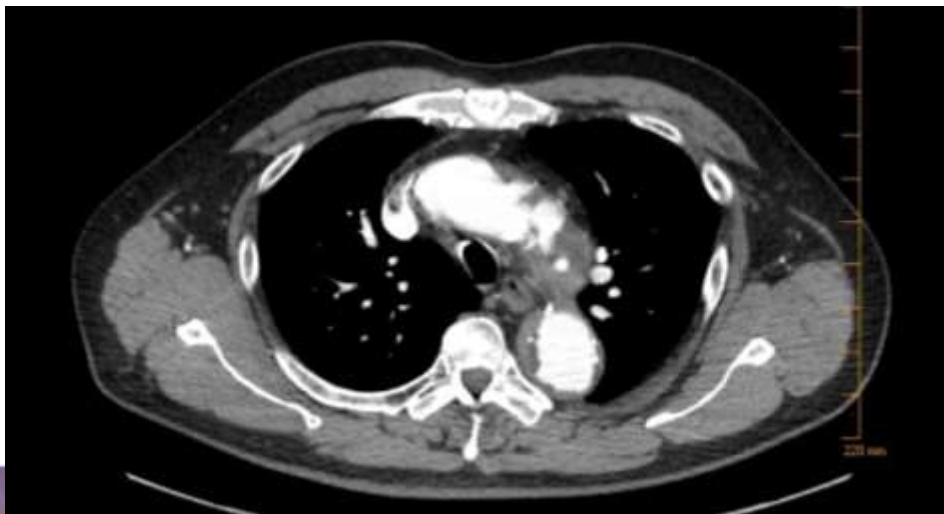
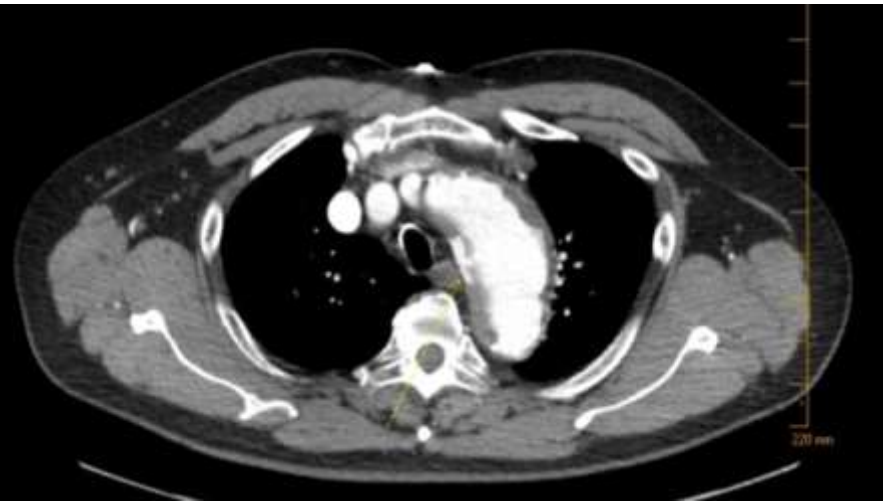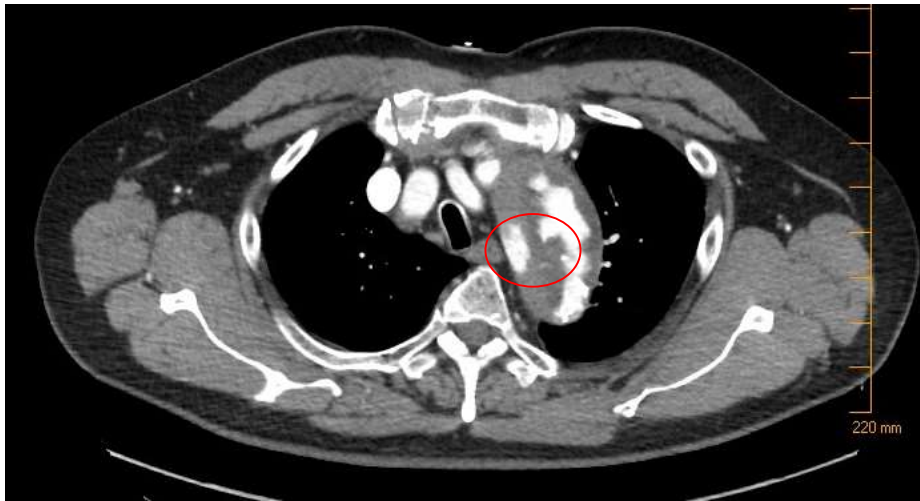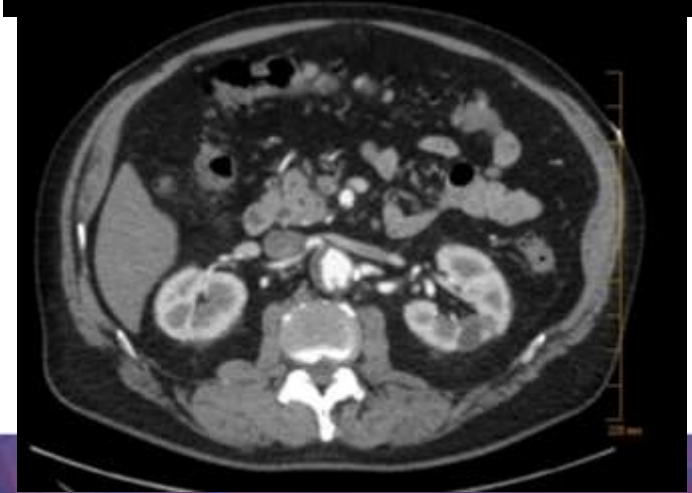
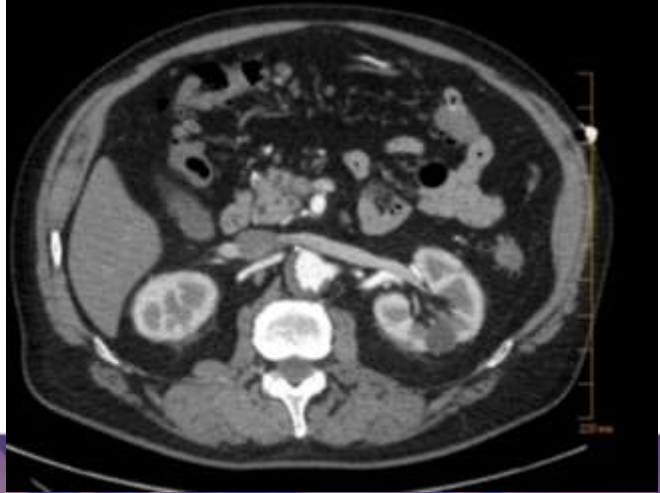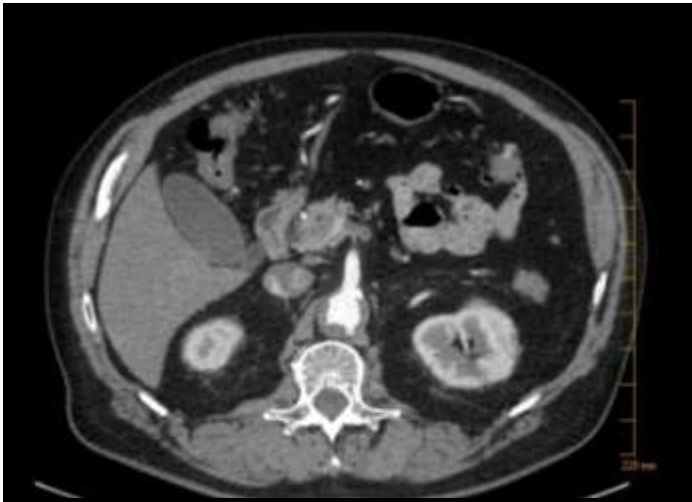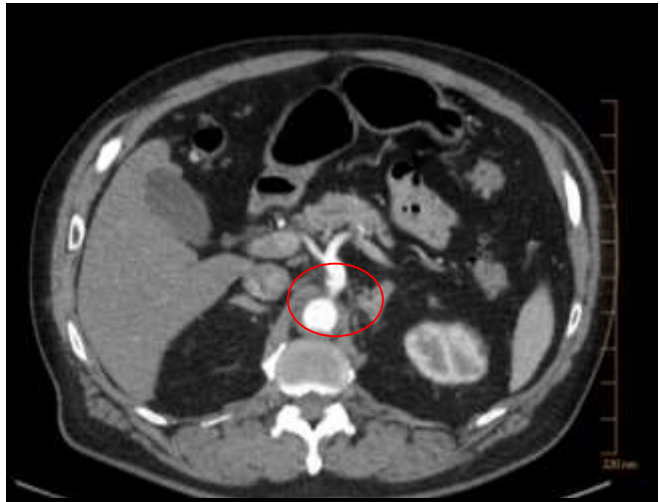
Worst Aortic Case of 2017

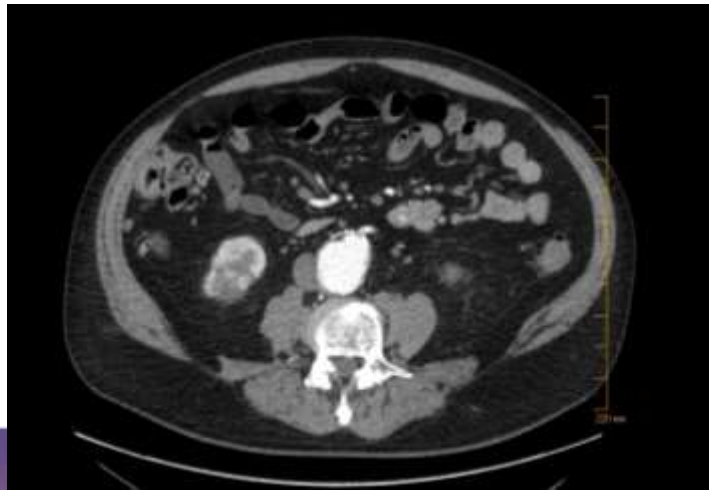
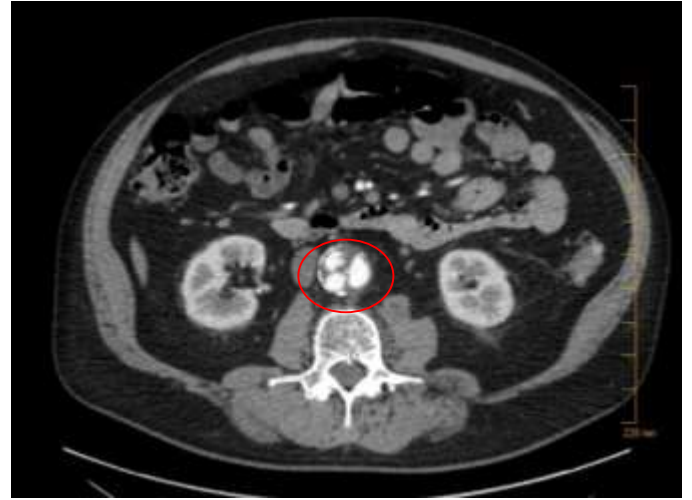
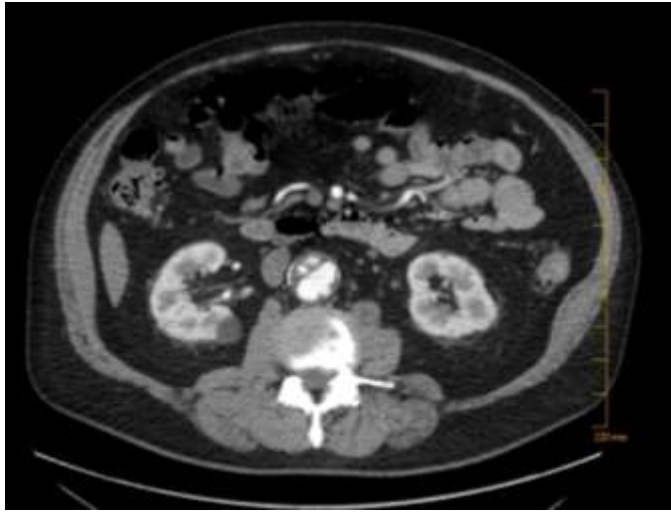*Peter A. Schneider, MD
Kaiser Foundation Hospital
Honolulu, Hawaii*

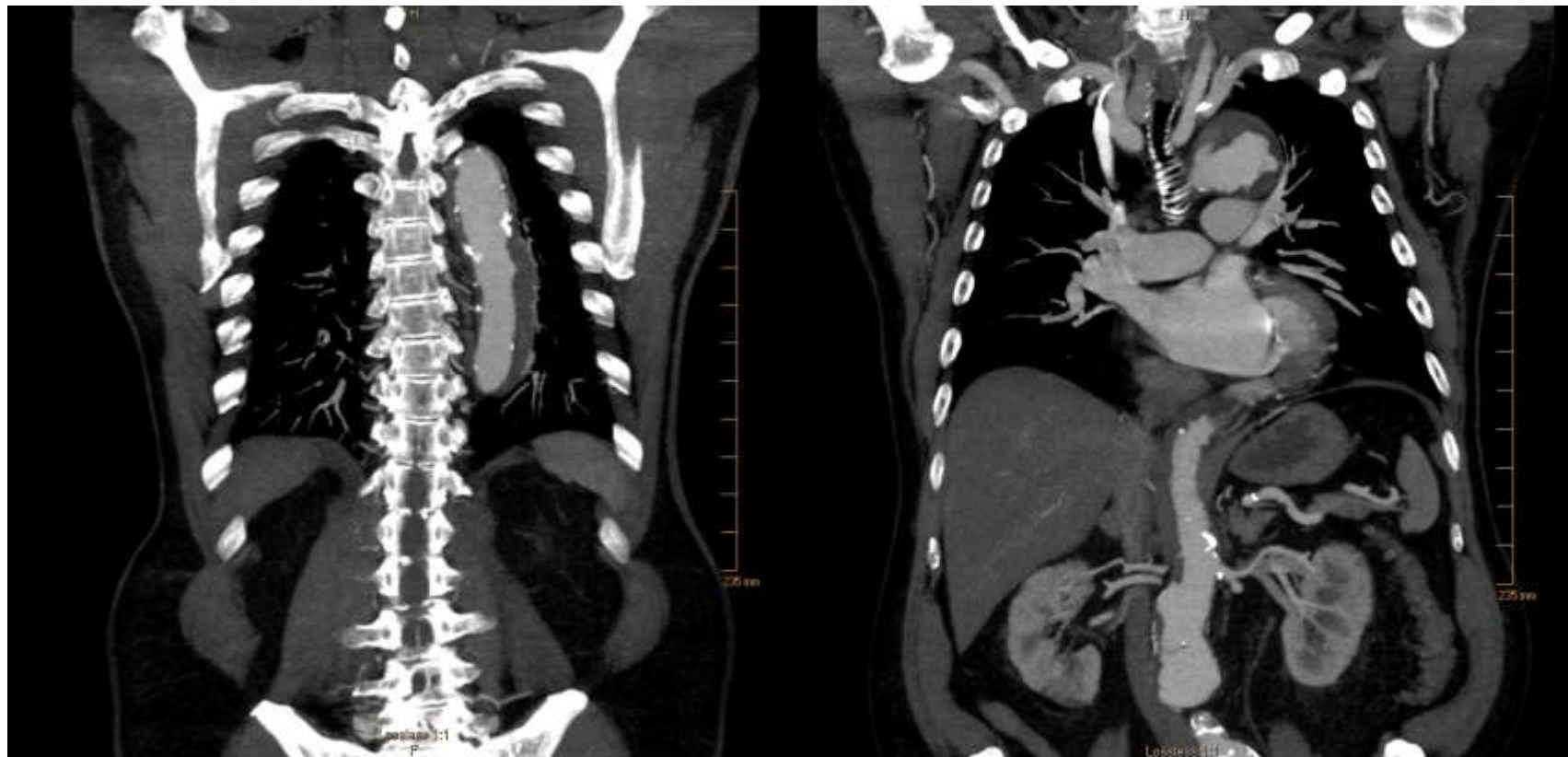62 year old man ER with chest pain

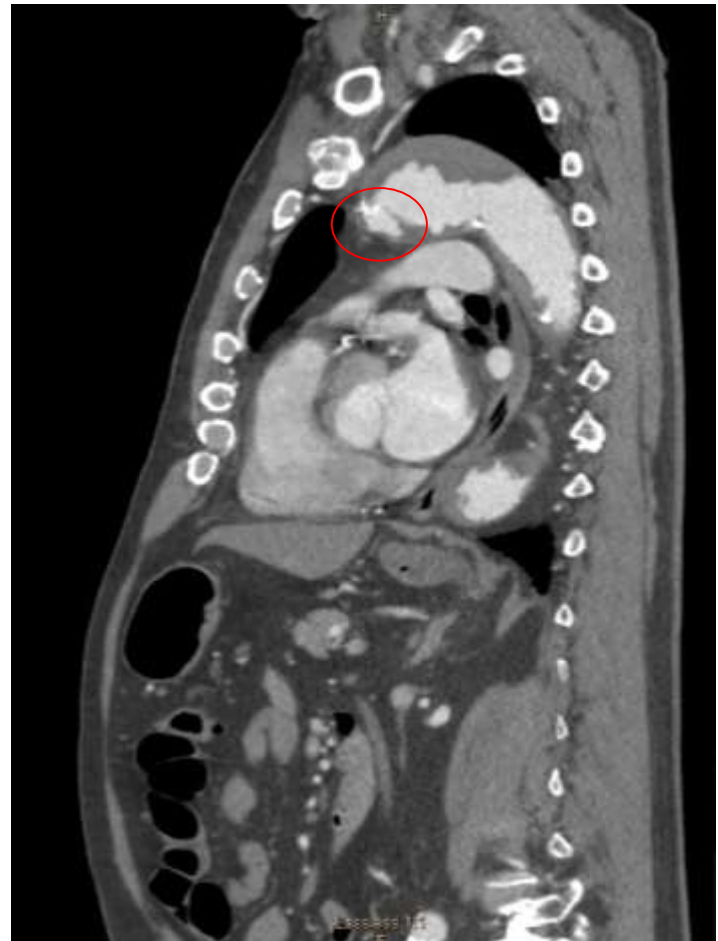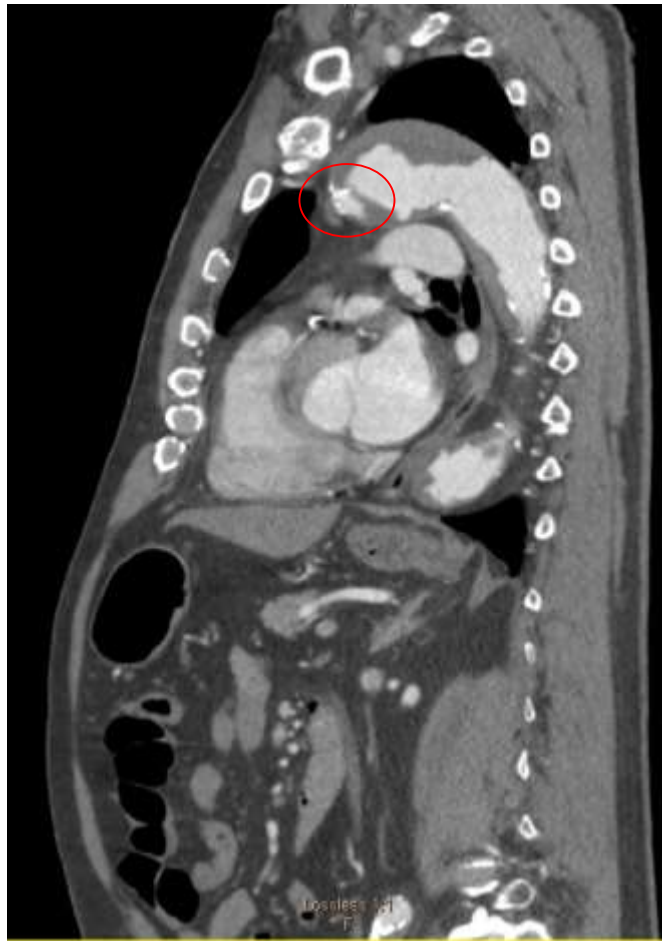- Awakened 5am
- 10/10 central chest pain
- No other symptoms
- EKG not suspicious
- 173/101











Chest pain resolved with BP control

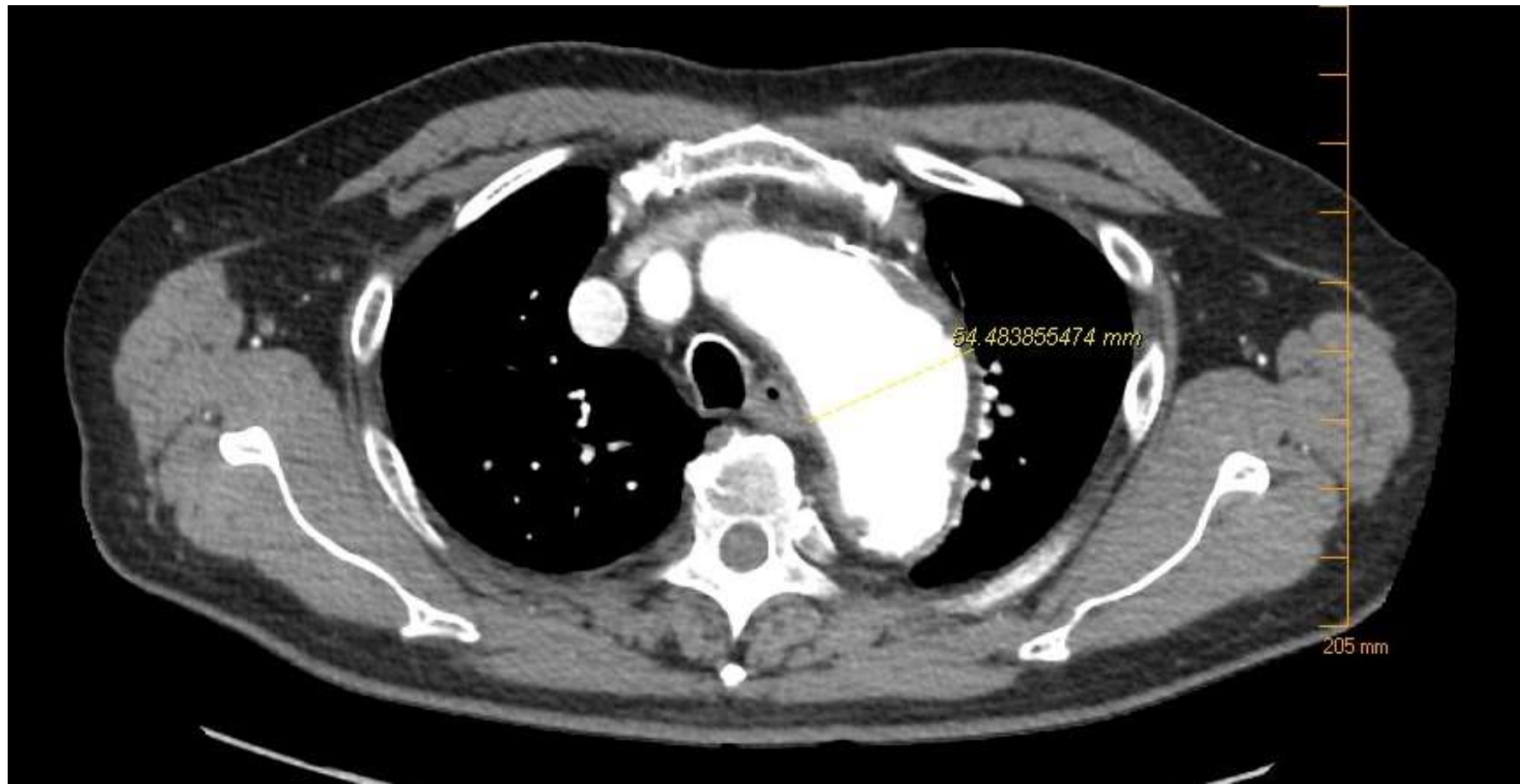- Arch diameter 4.3cm
- Quit smoking 5 years ago
- GFR 50 (CKD 3)
- CHF
- CAD
- COPD

Decision point

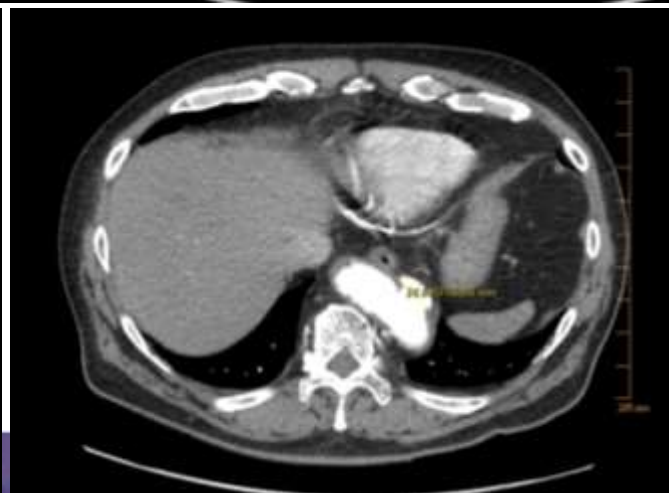
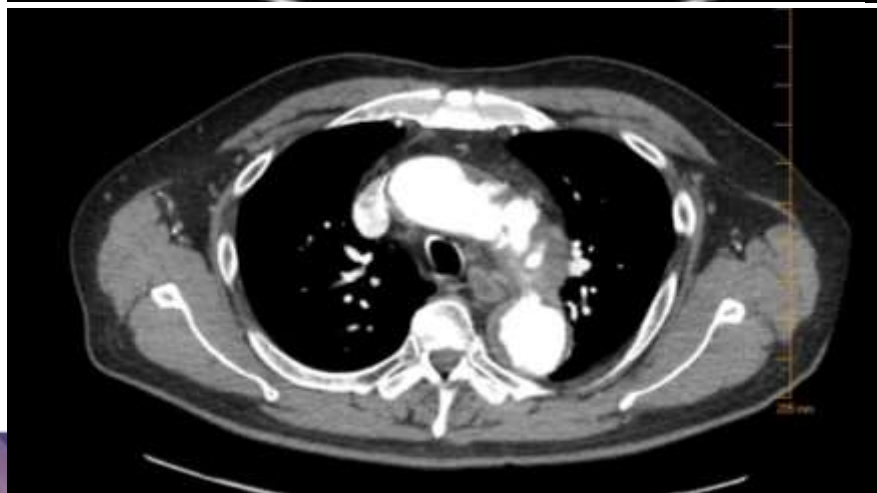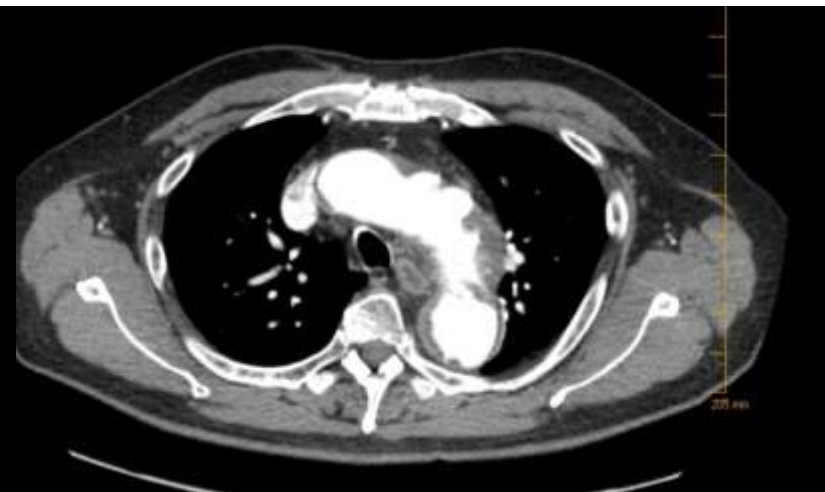
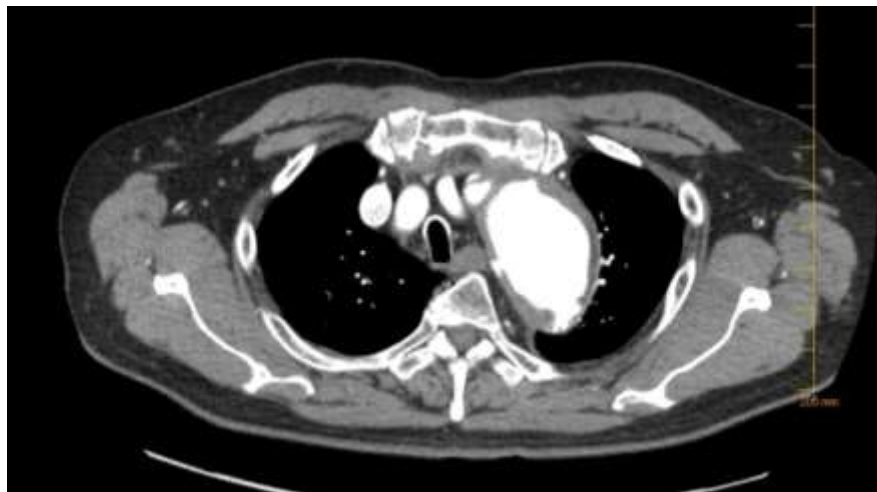- Repair vs Medical management
 - Indication for repair?
 - Risk of repair?
 - How to repair?

2 months later

- Chest pain 6/10
- BP 150/70-easily and quickly controlled
- Low grade chest pain continued

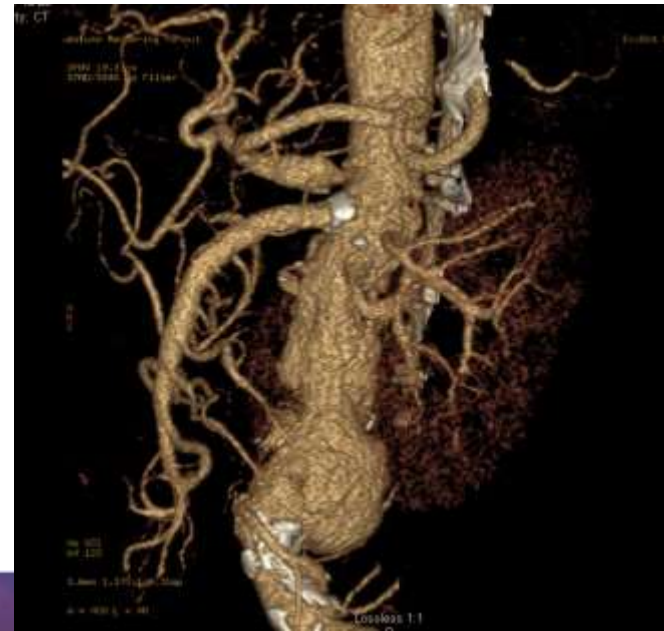
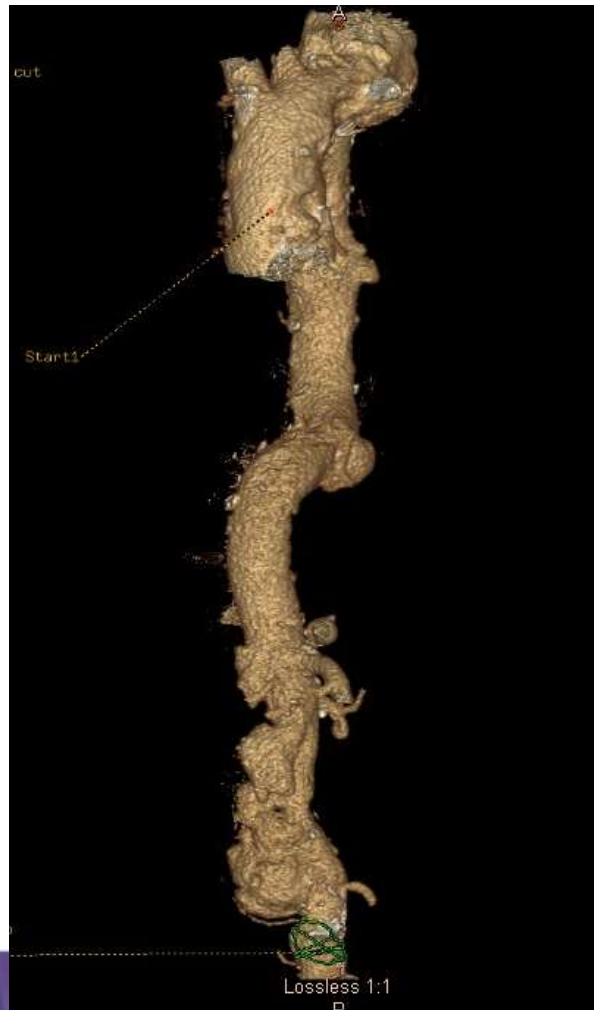
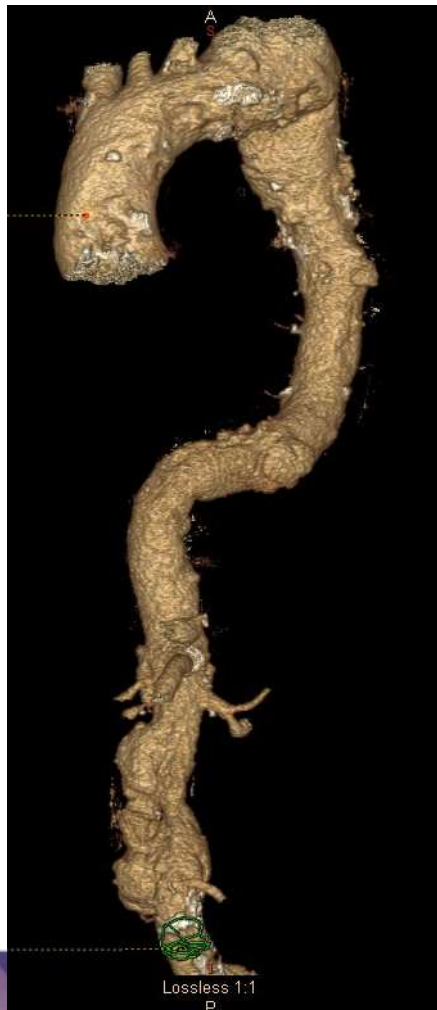Arch diameter increased from 43mm to 54mm



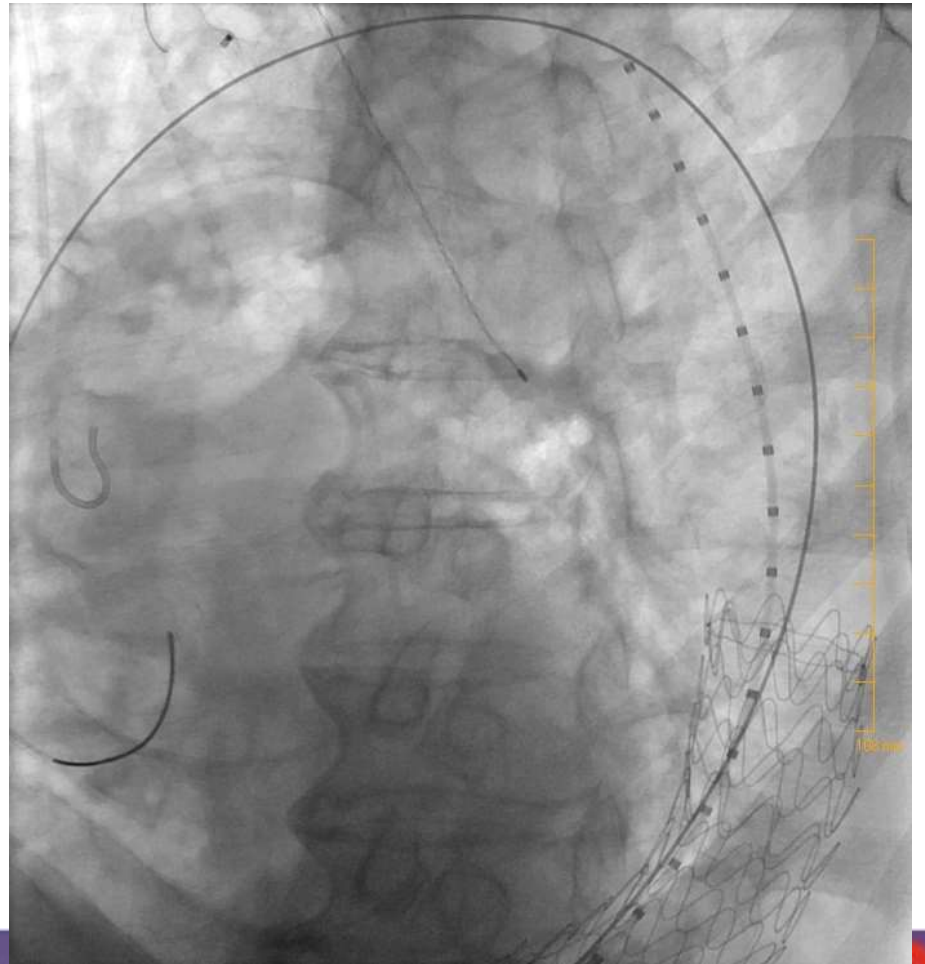
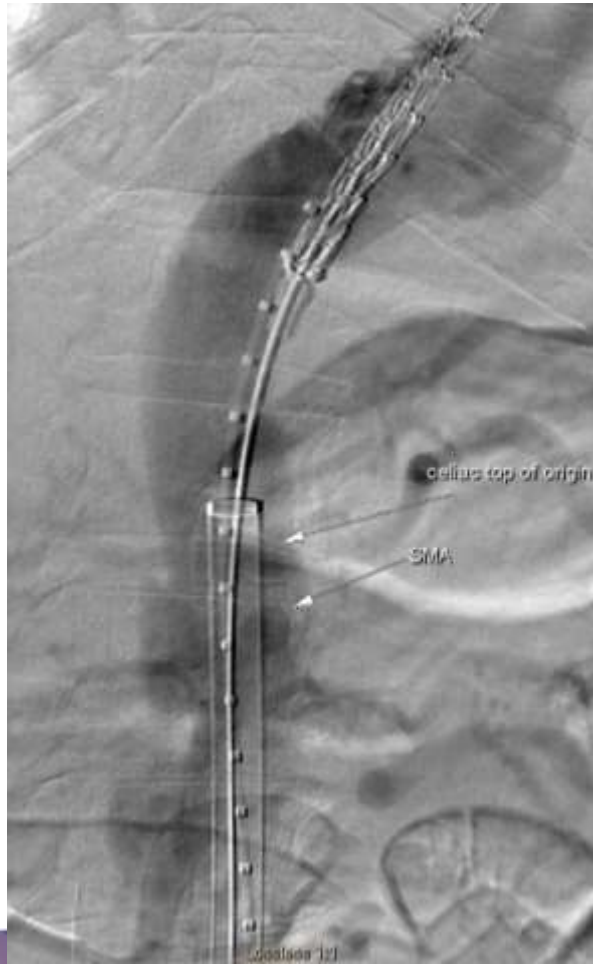Decision point

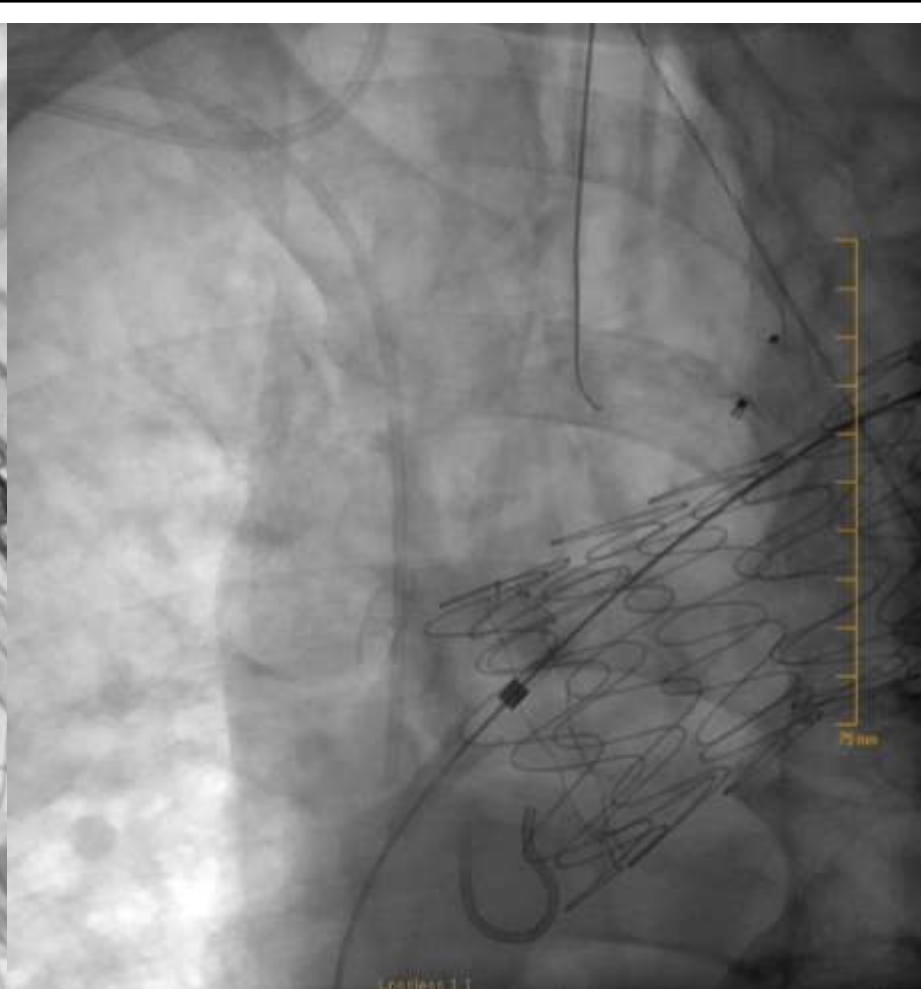
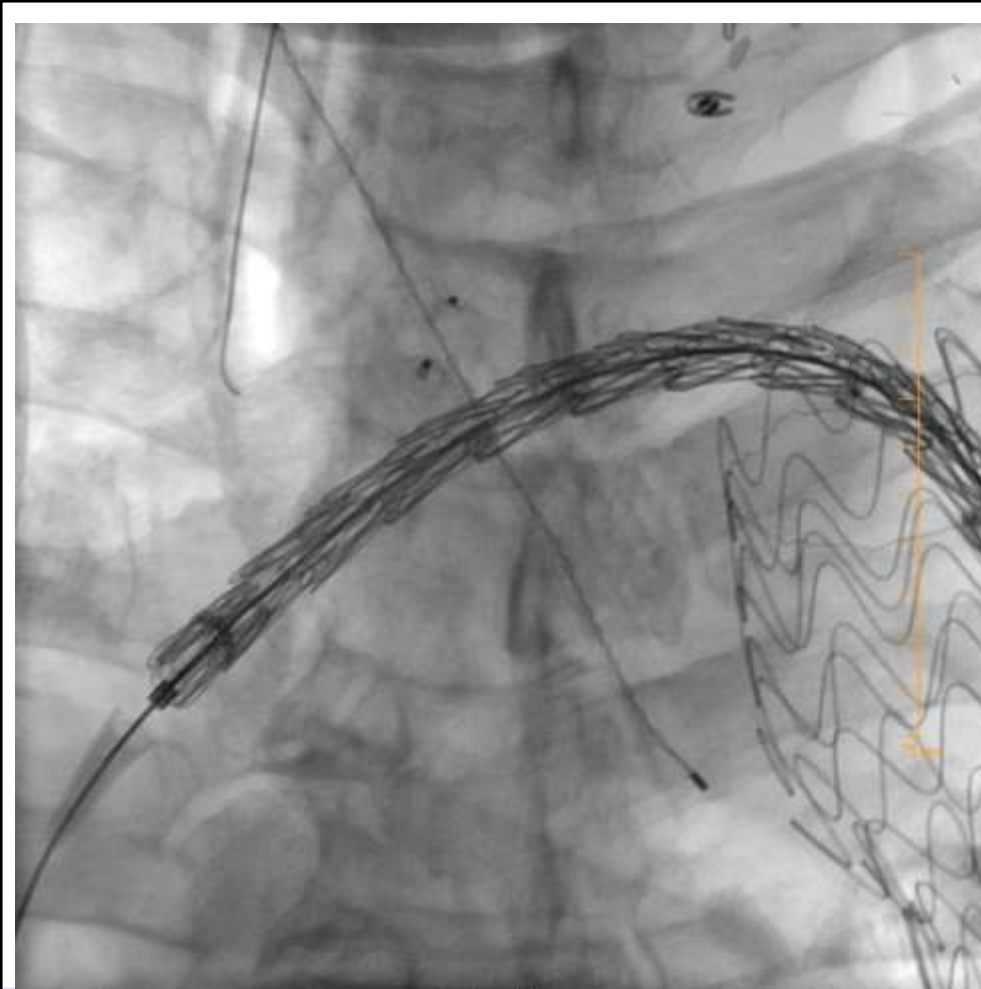
- Repair vs Medical management
 - Indication for repair?
 - Risk of repair?
 - How to repair?

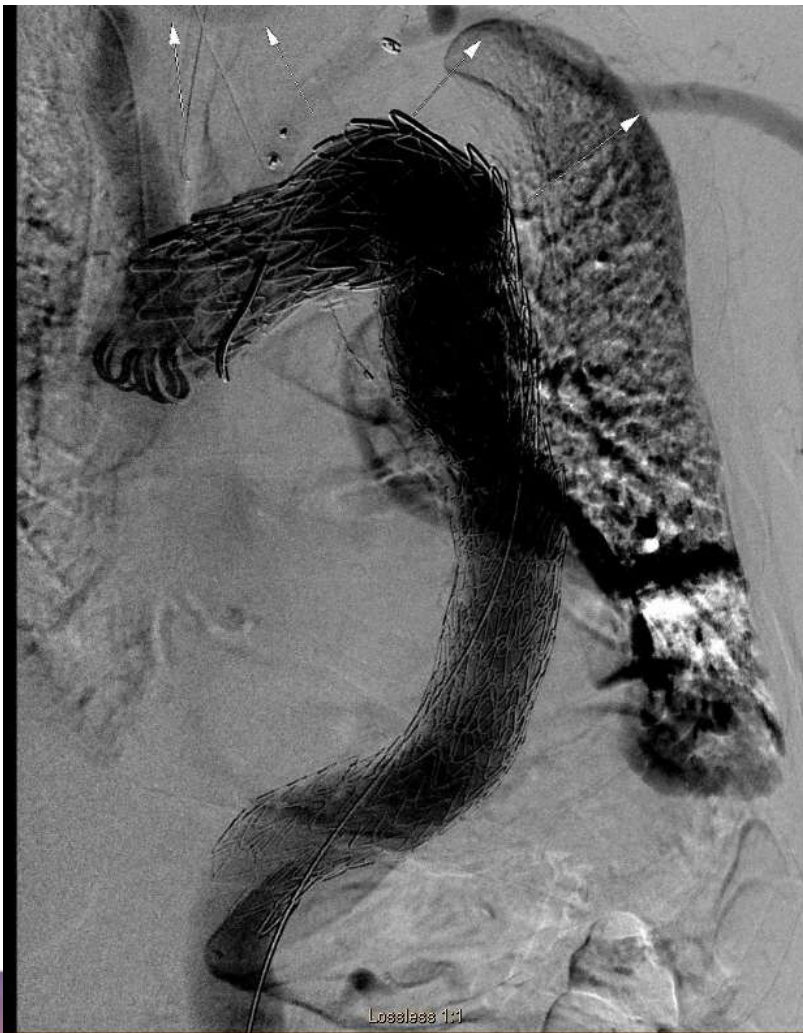

Plan

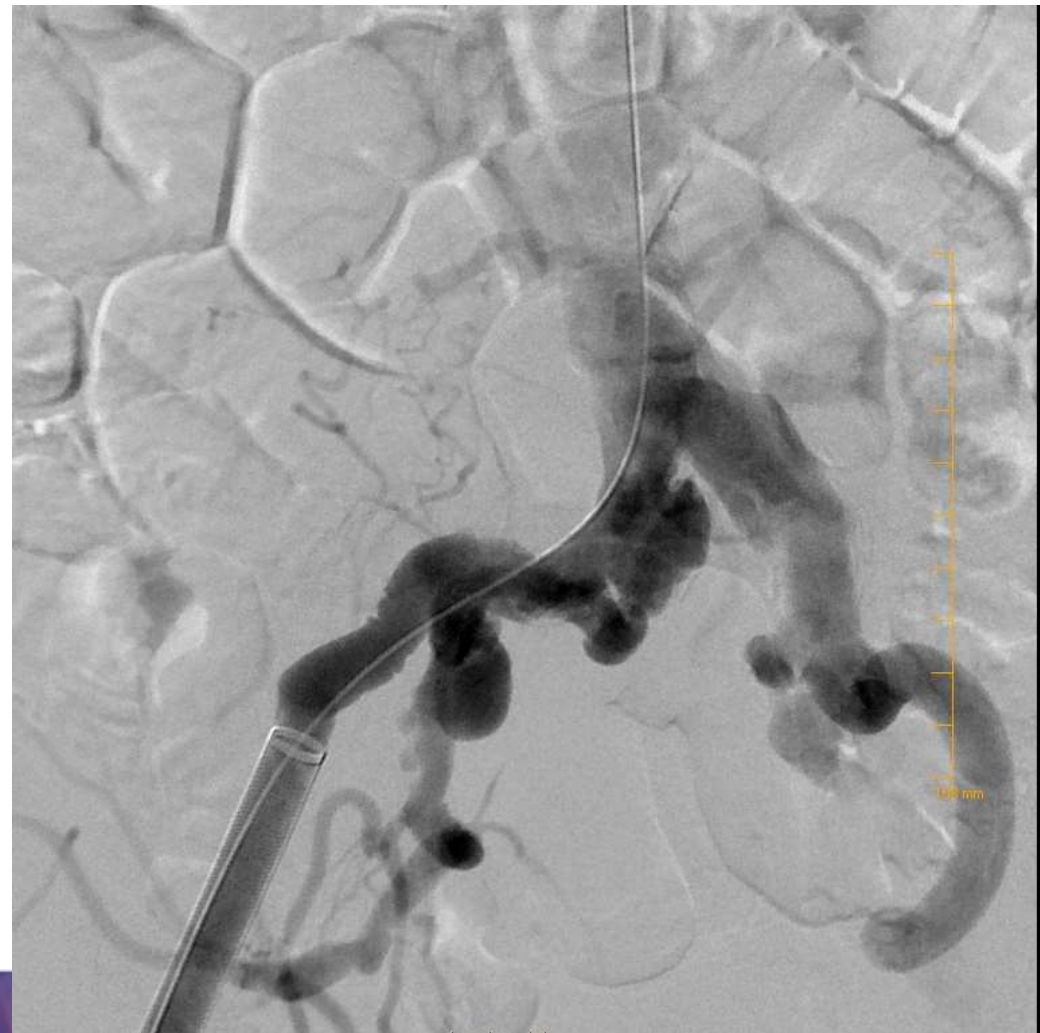- Carotid-carotid-left subclavian bypass
- Ligate proximal left carotid
- Plug proximal left subclavian
- Spinal cord protection
- Percutaneous approach
- Cover from distal to innominate to PAU in distal thoracic





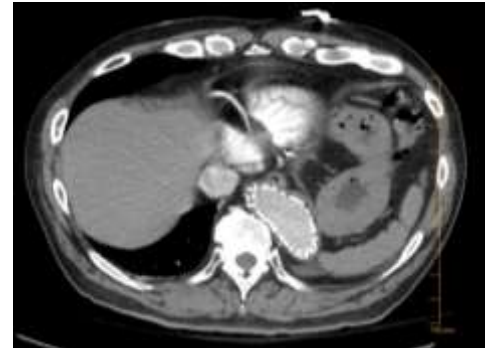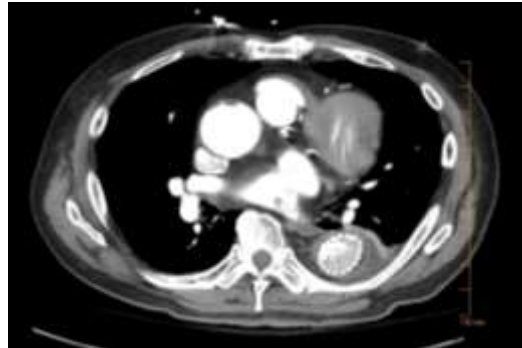
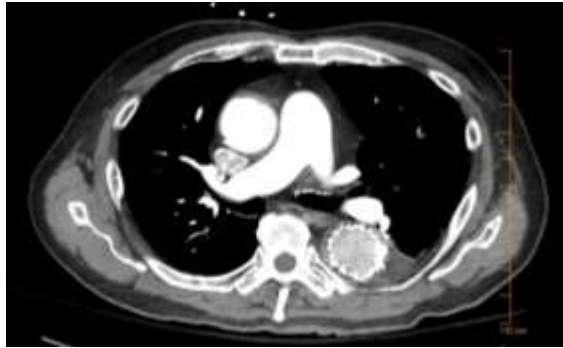
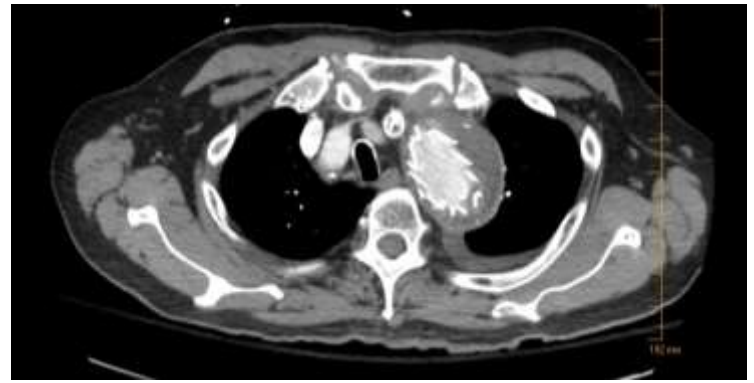
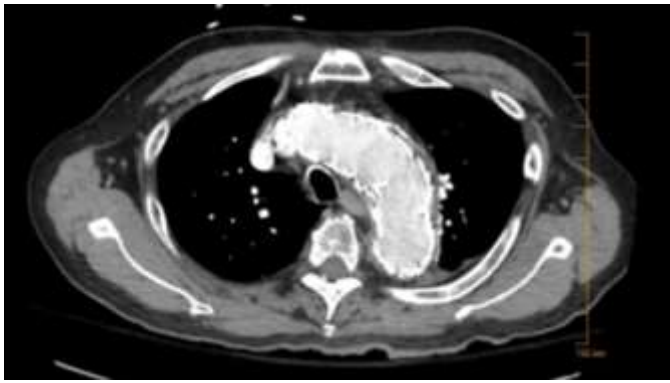


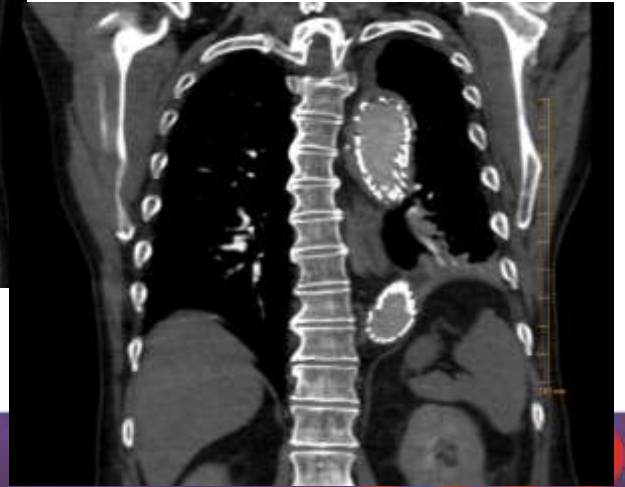
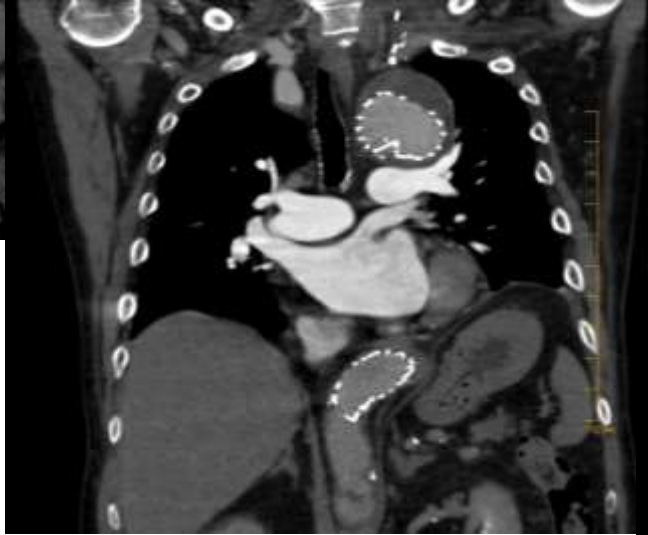
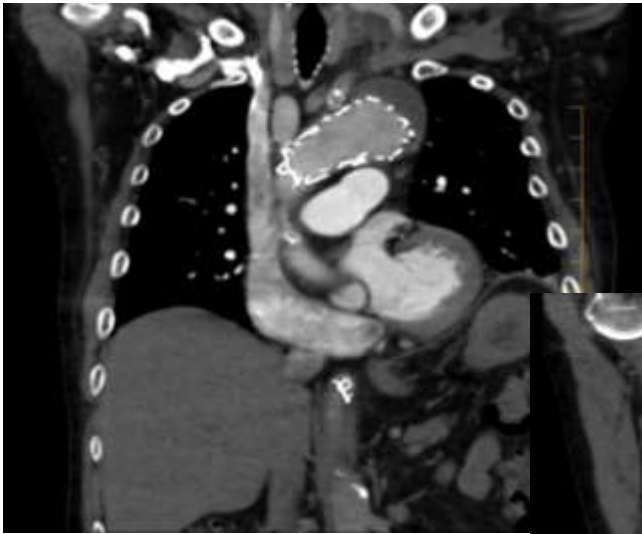
Losalae3 1:1



Plan

- Carotid-carotid-left subclavian bypass
- Cover from distal to innominate to PAU in distal thoracic
 - Gore 31x15, 37x15, 45x20





Discharged home after 2 days

17 days later

- Left arm weakness
- MRI brain and spine negative
 - spinal stenosis at C6

- Left leg and right arm weakness
- MRI: Infarct at C5, T1, T2
- Management?



November 5-8, 2018

at Wynn Las Vegas, Nevada, USA



NOVEMBER 4 - 5, 2018 • WYNN LAS VEGAS

The Venous Endovascular
INterventional Strategies

AT VIVA



*Attend the conference **live** from
your computer!*





Worst Aortic Case of 2017

*Peter A. Schneider, MD
Kaiser Foundation Hospital
Honolulu, Hawaii*