

A SINGLE CENTER EXPERIENCE USING AUTOMATED INTRACRANIAL PRESSURE-CONTROLLED CEREBROSPINAL FLUID EXTERNAL DRAINAGE

Lamarca MP¹, A Flores¹, PeinadoFJ¹, S Estébanez¹, B Méndez¹, D Soto¹, Arriola M¹, A Martín¹, Paz de D², A Orgaz¹

¹Vascular and endovascular surgery, Complejo Hospitalario Toledo, Spain

²Resuscitation service, Complejo Hospitalario Toledo, Spain

Disclosure

Speaker name:

María Pilar Lamarca Mendoza

I have the following potential conflicts of interest to report:

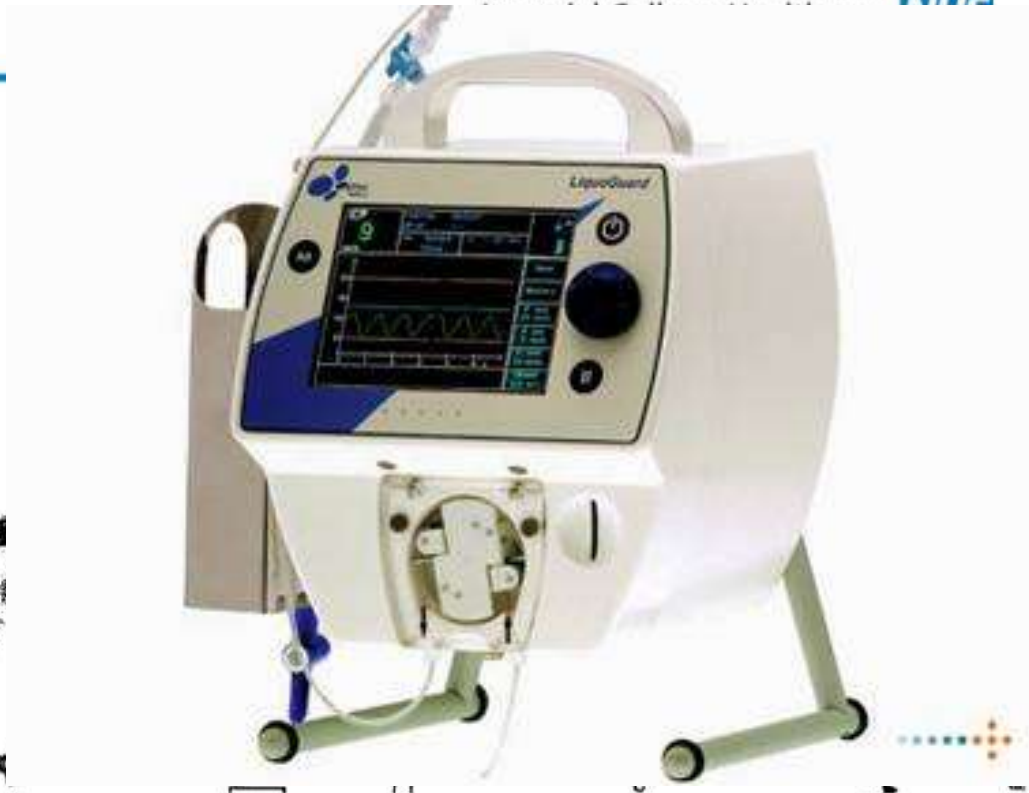- Consulting
- Employment in industry
- Stockholder of a healthcare company
- Owner of a healthcare company
- Other(s)

- I do not have any potential conflict of interest

AIM

Posterior

Latero-lateral connections



ie
muscles
scle

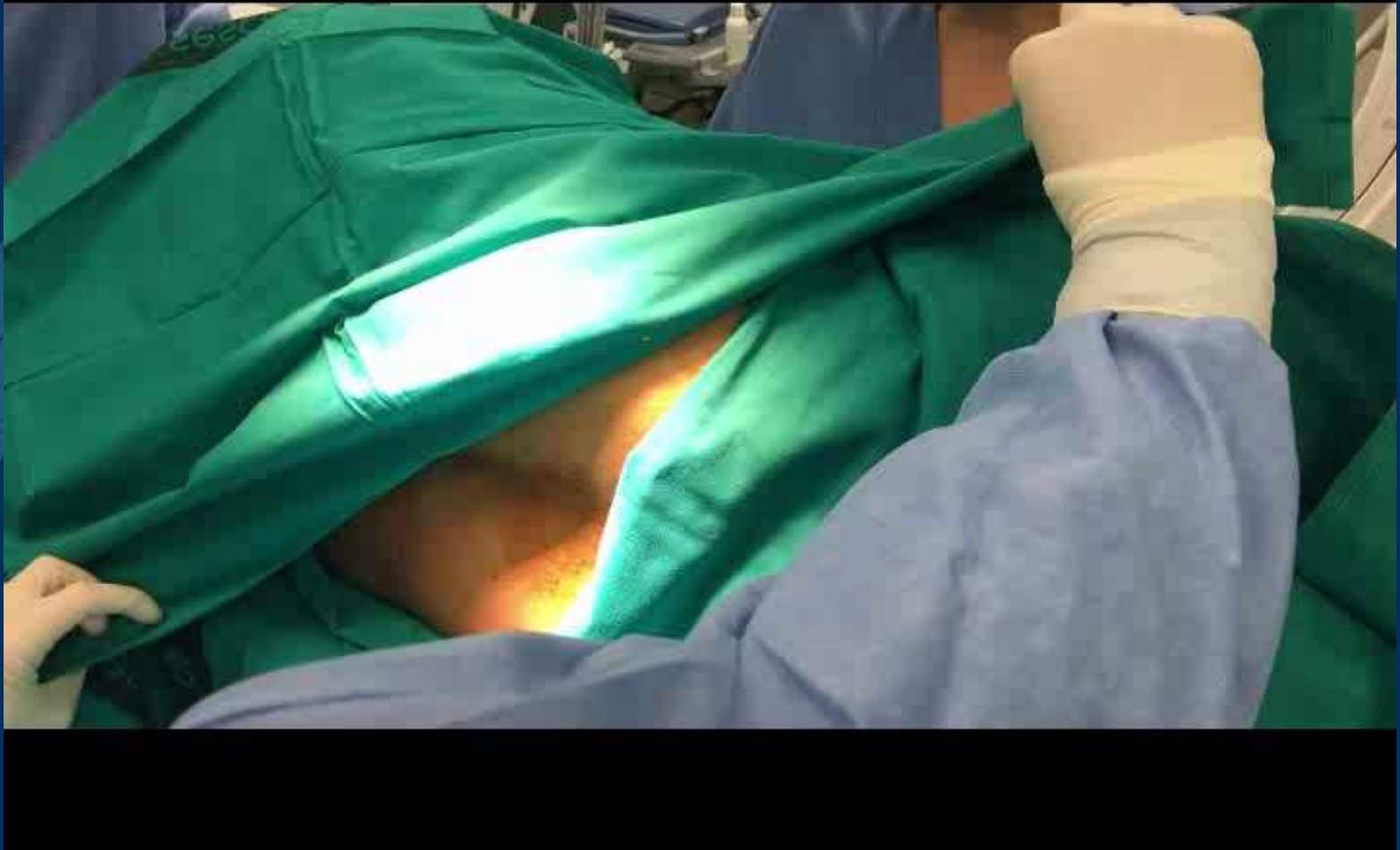Anterior



METHODS

RETROSPECTIVE

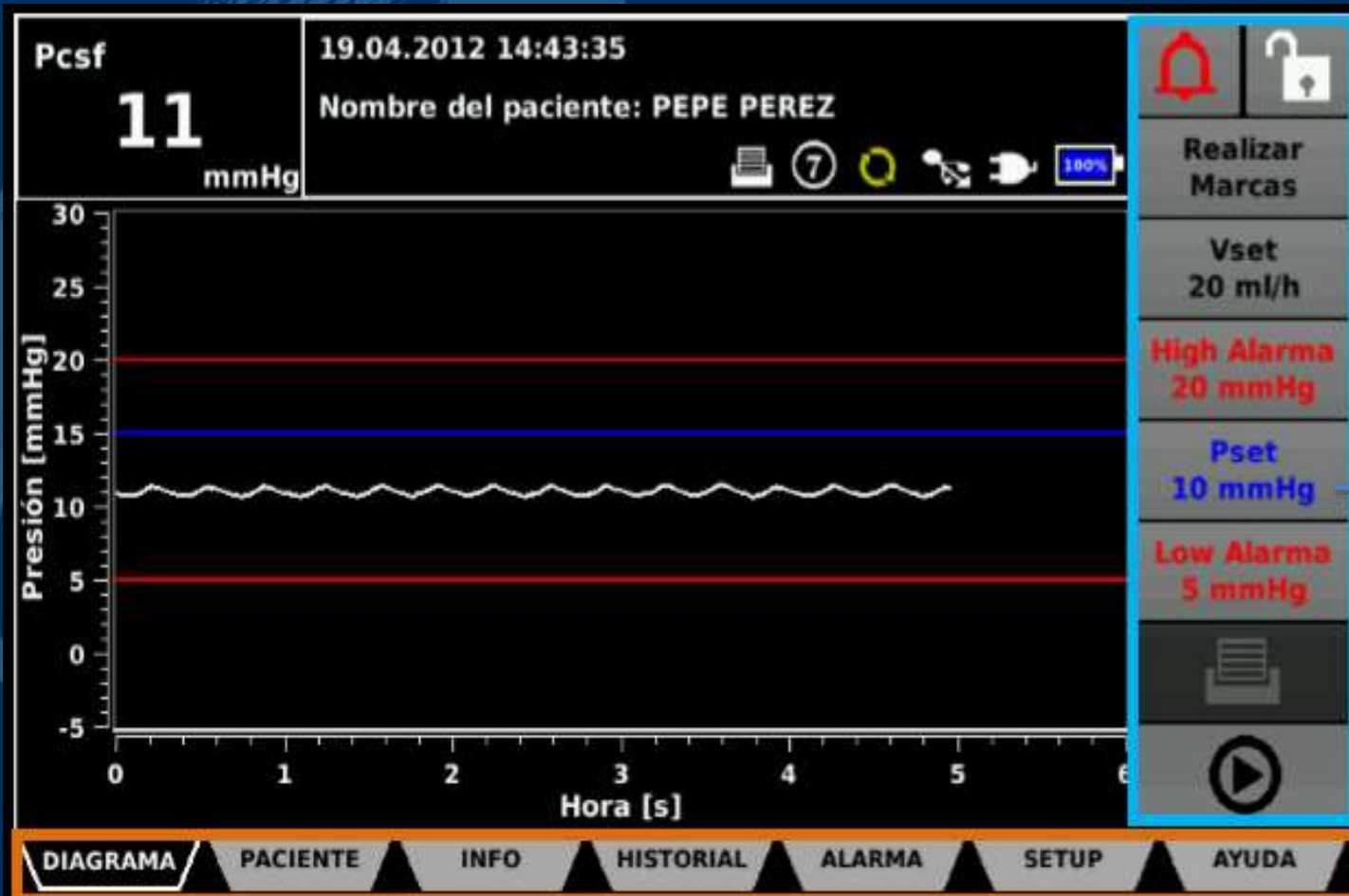
**THORACIC AORTA REPAIR
+
LIQUOGUARD**



>70 mmHg

CSPP = MAP - SCP

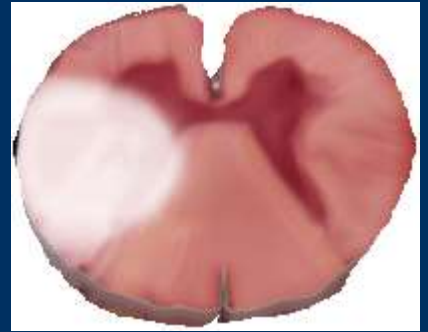
COMMON SETTING:



10 ml/h

10-12 mmHg

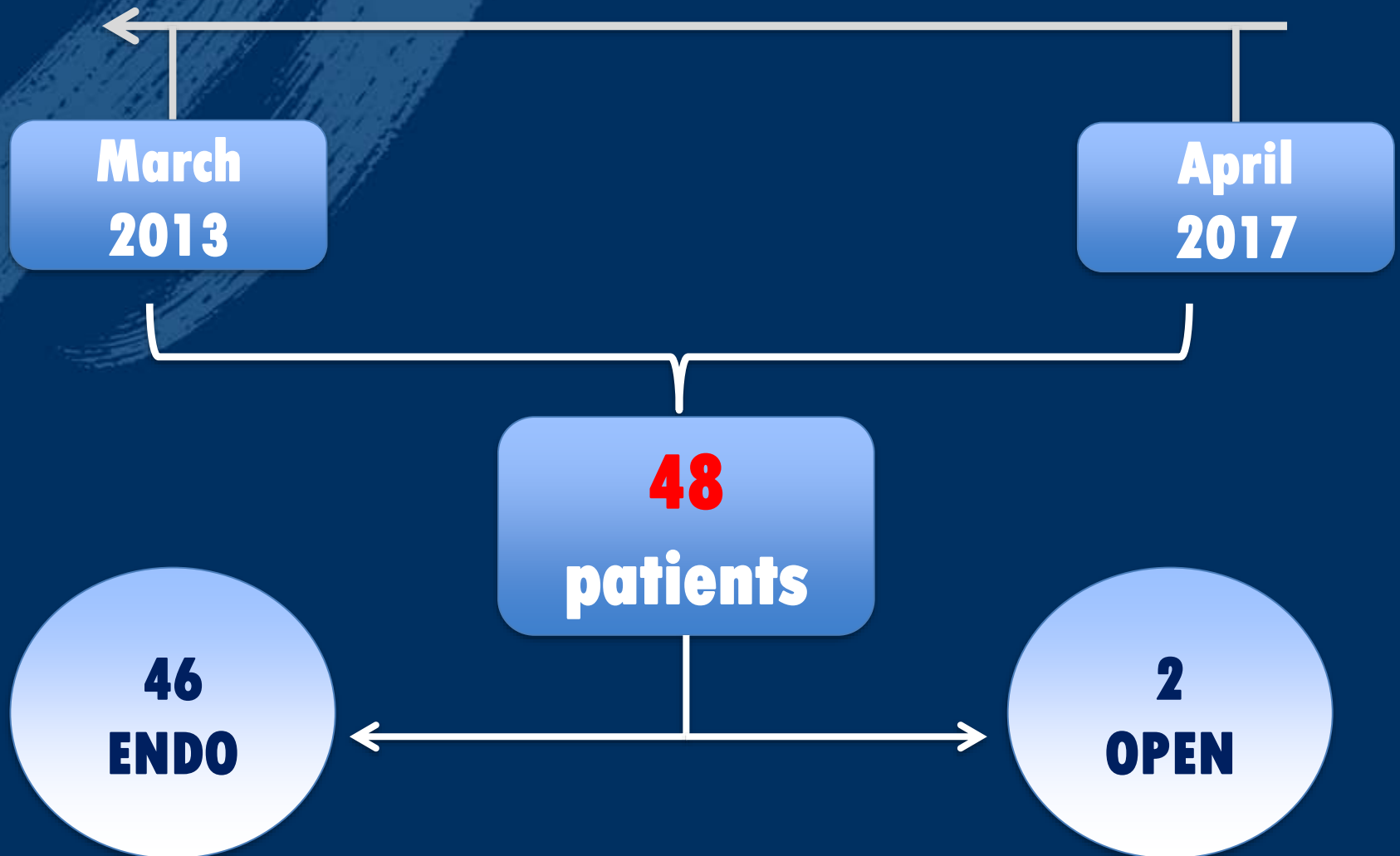
PRIMARY OUTCOMES

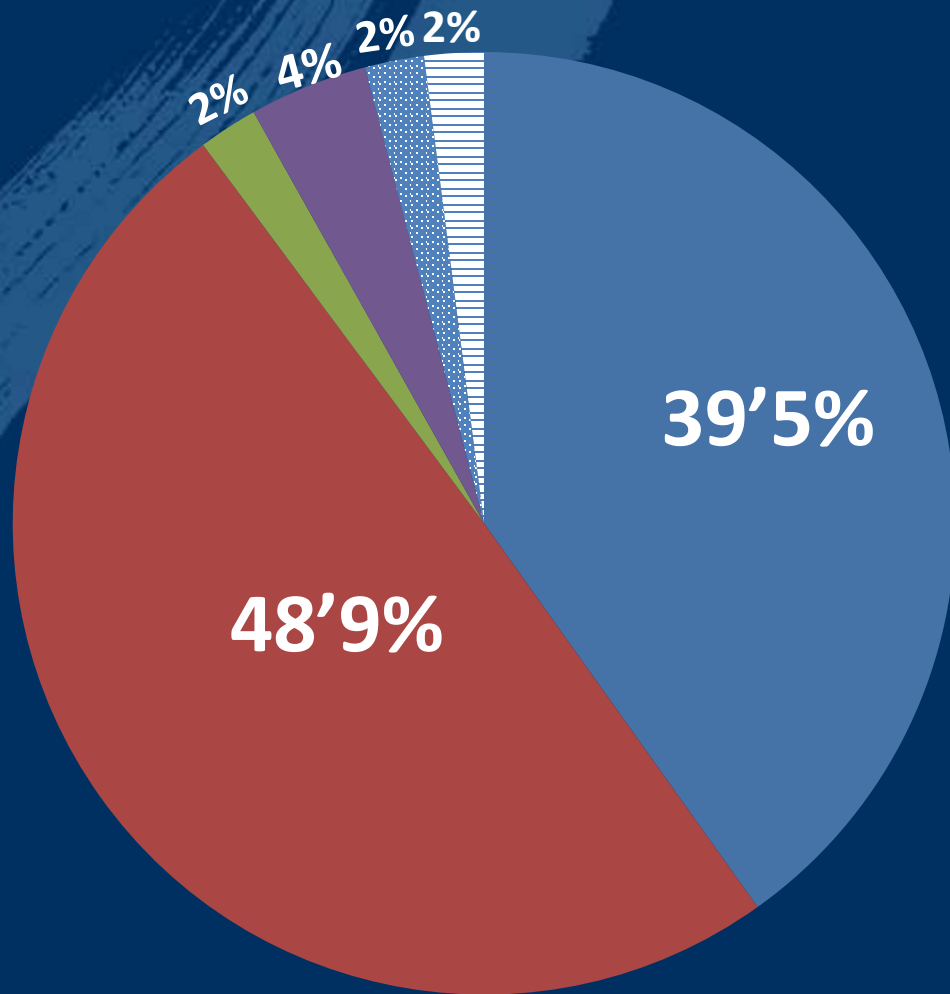








LUMBAR DRAINAGE RELATED COMPLICATION

SPINAL CORD ISCHEMIA
(transient or permanent)

RESULTS





-  **AAS**
-  **TAA**
-  **Stent fx.**
-  **endoleak**
-  **Pseudoaneurysm**
-  **Thrombus**

RISK PROFILE...

Prior aortic qx	14 (29%)
Primary LSA revascularization	13 (27.1%)
Covered LSA without revascularization	0
Mean covered aorta	204 mm
Extensive covered of descending thoracic aorta	32 (66.7%)
Open procedure	2 (4.1%)
Total visceral debranching	4 (8.2%)

48
INTERVENTIONS

0
SCI

1
INTRACRANIAL HEMORRHAGE



150 DAYS MORTALITY

Con



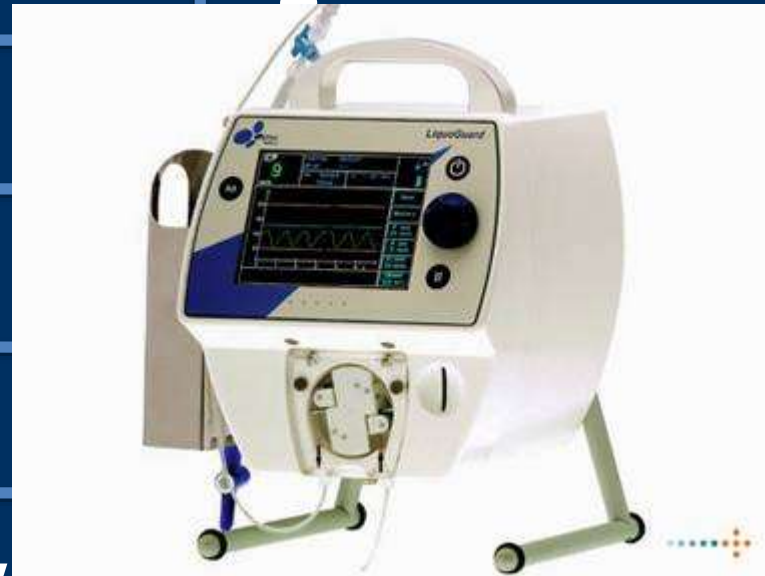e

n

a

m

own




1

1

TOTAL

6 (12.5%)

CONCLUSIONS



NO SCI

ted



THANKS!!!

A SINGLE CENTER EXPERIENCE USING AUTOMATED INTRACRANIAL PRESSURE-CONTROLLED CEREBROSPINAL FLUID EXTERNAL DRAINAGE

Lamarca MP¹, A Flores¹, PeinadoFJ¹, S Estébanez¹, B Méndez¹, D Soto¹, Arriola M¹, A Martín¹, Paz de D², A Orgaz¹

¹Vascular and endovascular surgery, Complejo Hospitalario Toledo, Spain

²Resuscitation service, Complejo Hospitalario Toledo, Spain